

# "...AND THIS LITTLE PIG..."

## RULES

Biology

Grades 9-12

Changes to the rules are marked by a vertical line

In this event teams of 3 to 6 will be expected to develop careful dissection techniques and become familiar with the name and location of the major structures of the circulatory, respiratory, digestive, and urogenital systems as described in the dissection guide to be provided. Students should be able to enter the thoracic and abdominal cavities quickly. A basic knowledge of the function of major organs will also be assumed.

Non-dissected male and female specimens will be provided on the day of competition. Students must bring to the competition their own dissecting kit and gloves, and a pen or pencil for answering the question sheets.. Each kit may include 1 scalpel, 1 spare scalpel blade, 1 probe, 1 pair of tweezers, 1 pair of dissecting scissors, and 1 box of T-pins. Students will be allowed to open up the thoracic and abdominal cavities, identify structures (approximately 15) and complete a dissection questionnaire regarding structure, function and physiology of organs.

### Sample Directions

1. Insert a green pin into the gall bladder.
2. Insert a red pin in the organ which is the site of sperm production.

3. Clear the tissue from the region anterior to the heart and insert a black pin in the right subclavian artery.

4. Name the tube that drains the bladder.

Each year, a particular system will be designed for special study, and this will be announced on the web page.

### Scoring

- i) Each dissection will be marked out of 100%. Structures must be clearly displayed.
- ii) Written answers to questions will be marked out of 100%
- iii) The final mark will be calculated using the following weighting: 65% dissection (i above) and 35% questions (ii above) to give a total mark out of 100%.

### Questions

- | If there are any questions, please contact Elizabeth Heinicke at 473-5695.

## 1. INTRODUCTION

In 1680 Edward Tyson published *Anatomy of a Porpoise* after dissecting a specimen which had found its way up the Thames River and into a fisherman's net. He found this animal to be much more like a four-legged mammal than fish. Similarly, the dissection of a Malaysian "orang-outang" by Tyson and William Cowper in 1699 clearly showed the kinship of man and

# DISSECTION OF THE FOETAL PIG

## GENERAL RULES FOR THE DISSECTION OF ANIMALS

1. **READ** the directions carefully before you begin to dissect.
2. **IDENTIFY** the structures to be cut before cutting them.
3. **LIFT** structures to be cut with forceps or probe.
4. **CUT** only what is absolutely necessary.
5. **EXPOSE** structures completely and cleanly to view

### Glossary of anatomical terms:

dorsal:	near or toward the back
ventral:	near or toward the belly
anterior:	near or toward the head end
posterior:	near or toward the hind end
pectoral:	relating to the chest and shoulder region
pelvic:	relating to the hip region


### Instructions for dissection:

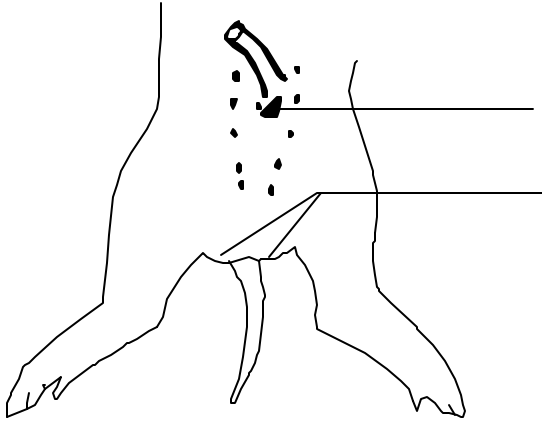
Care in dissection is essential. You must be attentive and patient as you work. You should know where you are cutting and why you are cutting. If you are not sure of your ground, go slowly, inspecting each step.

Your dissecting kit contains a number of different instruments. Perhaps scissors are the most useful of your tools. They can be used to cut, or to spread or separate, but remember that when you are cutting into something, keep the round or blunt arm of the scissors inside, and the hidden point turned up as much as possible to avoid chopping through internal structures. Your scalpel should only be used occasionally to cut through firm, thick tissue. The difficulty with a scalpel is that you never know how deep you are cutting, or what is being sliced beneath the layer in which you are

interested. Forceps are handy for holding things aside, or as a probe when closed. A probe is used to push things aside, to penetrate into chambers, to trace out blood vessels, etc., and to scrape away connective tissue. This is probably your most frequently used tool. Dissecting needles can be used cautiously as probes, or to hold things down, or as fine scalpels to cut through very delicate tissues.

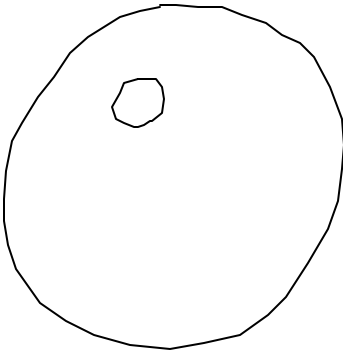
When dissecting make sure the structure you are seeking gets exposed as completely and cleanly as possible. Do not stop at the first glimpse of it; do not give up if it does not pop immediately into view. To dissect means "to cut away from". Do that. Be sure you see all the structures mentioned in this manual.





**Figure 3** *Male Pig Posterior Ventral Region*

**Umbilical Cord:**



1. 51 186 8.5 125 4377 51.5 11.



May 8, 2002

**below.** As you approach the cord, lift it up and watch for the umbilical vein, which runs from the inside of the cord across to the liver.

2. Extend the cut diagonally on either side of the umbilical cord until you reach the thick tissue of the legs. Now cut the umbilical vein in the middle so that this structure may be identified later.

3. Locate the *diaphragm*, a sheet of muscle which runs right across the *coelom* (body



portion of the duodenum.

5. Find the end of the small intestine where it enters the large intestine. The blind end of the large intestine, the *caecum*, projects out. (In human beings the appendix is a finger-like projection on the end of the caecum.) The last part of the colon runs posteriorly down the dorsal abdominal wall. The very end is the *rectum* which is not visible at this time.

6. On either side of the descending colon, note the large *kidneys* which are covered by the *peritoneum*, the shiny lining of the abdominal cavity.

7. Running down the inside of the flap made by cutting on either side of the umbilical cord, note the continuation of the *umbilical arteries*, and in between these, the urinary *bladder*.

*posterior vena cava* (blue) which runs into the liver.



## Thoracic Cavity

1. With scissors cut the connections between the pig's **left** lung and the heart. Remove and examine the left lung. You can see the left *bronchus*, leading into the lung and also cut sections of the left *pulmonary artery* and *pulmonary vein*.

2. Running down the mid-dorsal wall of the thoracic cavity is the *dorsal aorta*. Because the aorta is thick-walled it appears white, but if you nick it with your scalpel you will find that it is usually filled with red latex.

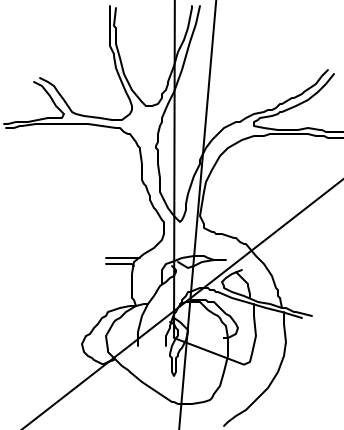
3. Ventral to the aorta is the oesophagus. The fine strands of the *vagus nerves* may be seen on either side of the oesophagus.

4. Ventral to the oesophagus, locate the

4. We will not identify most veins below the diaphragm in this exercise because they often fail to pick up blue latex but you will see the *renal veins* which drain the kidneys at a later time, and you have already identified the umbilical vein.

### Arteries around the Foetal Heart

1. In order to preserve the veins anterior to the heart, cut the anterior vena cava just anterior to the heart and lift the venous system up. Don't cut too deeply. Important arteries lie immediately below.



brachiocephalic artery.

### **Adult Circulation of Blood through Heart**

In the adult, blood from the anterior and posterior vena cava enters the right atrium, flows to the right ventricle, out the pulmonary trunk and down the pulmonary arteries to the lungs. From the lungs blood enters the left atrium via the pulmonary veins, flows to the left ventricle, and out the aorta to the body.

### **Foetal Circulation vs Adult**

The pattern of foetal circulation differs in a number of ways from the adult. For example, blood rich in oxygen and nutrients enters the foetus by way of the umbilical vein, passes through the liver into the posterior vena cava, and from there into the right atrium. An opening between the right atrium and the left atrium called the *foramen ovale* allows some of the oxygen-rich blood to flow from the right to the left side of the pig's heart. From there it is distributed by the aorta and its branches to the head and body.

### **Do not try to locate the foramen ovale.**

The heart and its surrounding arteries should be left in position in the pig.

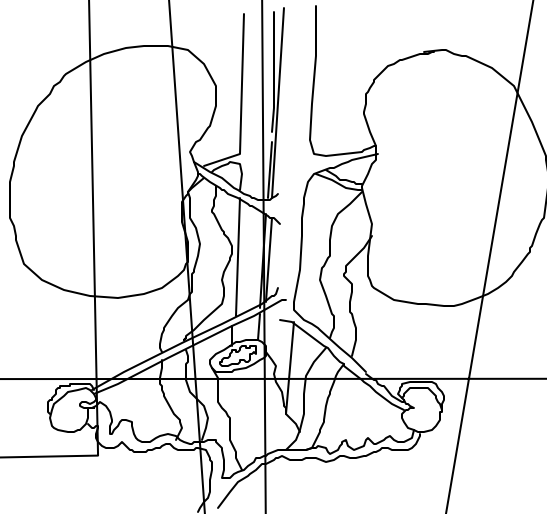
Another foetal adaption, which you just identified is the *ductus arteriosus*. Blood leaving the right ventricle passes along the pulmonary trunk on its way to the lungs. While some blood flows into the lungs via the pulmonary arteries, most of it continues straight into the aorta via the *ductus arteriosus*, which is a foetal connection between the pulmonary trunk and the aorta. After birth, the foramen ovale closes and the ductus arteriosus constricts

so that the adult pattern of circulation is normally achieved. In addition, the umbilical vein and umbilical arteries atrophy.

## Urogenital System - Female

1. Examine the pig's left kidney. It actually lies outside of the abdominal cavity behind the peritoneum. Leading from the kidney to the bladder is the *ureter* which may be seen through the peritoneum. The *adrenal glands* are narrow bands of tissue at the anterior end of each kidney facing the aorta. Break the peritoneum with your probe along the median (inner) edge of the kidney and locate the *renal artery and vein*.


2. The *ovaries* are a pair of small bean shaped organs in the posterior end of the abdominal cavity. They are supported by a mesentery (attaches organ to body wall) called the *broad ligament*. Running along the edge of the broad ligament are the wavy left and right *horns of the uterus* which meet in the midline to form the *body of the uterus*.



Note that this shape of uterus is common among animals which produce several young at once. The developing piglets are strung out along the horns of the uterus. The body of the uterus is merely a passageway which leads to the vagina.

3. Examine the end of one horn of the uterus near an ovary. It narrows to form a convoluted *fallopian tube* which runs along the side of the ovary.

4. The body of the uterus disappears into the floor of the abdominal cavity. To expose the rest of the female urogenital system you must make a mid-ventral incision with your scalpel. Keep the flap containing the *bladder* pulled over to the pig's right and cut straight down the



4. To expose the rest of the male system, pull the flap containing the bladder over to the pig's right and make a mid-ventral incision with your scalpel. Cut right down the midline, pressing the legs out. You will be cutting through the pelvic girdle, which should open up to expose the *urethra* underneath.
5. Clear the connective tissue with your blunt probe and trace the urethra posteriorly from the bladder. Just past the bladder on the *dorsal* side are the pair of *seminal vesicles* (at the point where the two ductus deferens enter the urethra).
6. Follow the urethra down under the pelvic girdle. On either side, identify the large *bulbourethral* glands.
7. As the urethra approaches the most posterior end of the pig it becomes very difficult to separate it from the surrounding connective tissue. In this region the urethra enters the *penis*. Locate the penis, which runs forward along the ventral abdominal wall, by cutting through the skin, and trace the penis to the opening just posterior to the umbilical cord.
8. Dorsal to the urethra and bulbourethral glands observe the posterior portion of the descending colon which terminates in the lighter coloured *rectum*.